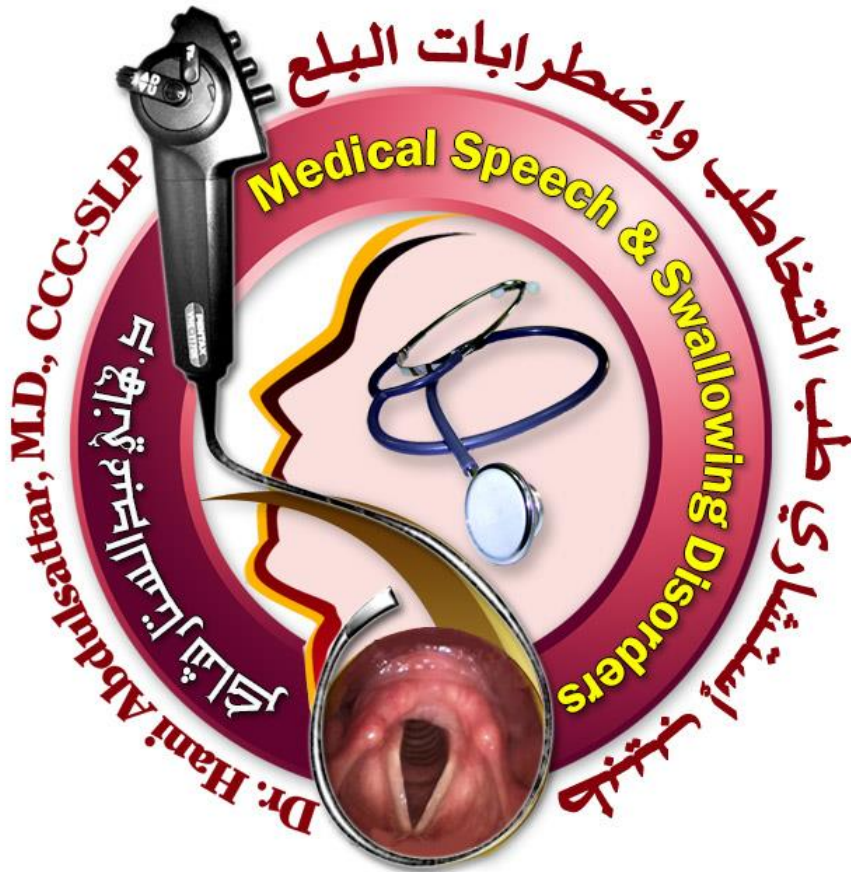

# Clinical Physiology of swallowing Mechanism

Dr.Hani Shaker



# The Physiology of swallowing

- \* If a bolus is completely cleared through the pharynx, it must be concluded that the structural movements associated with that swallow were functionally adequate, even if they appeared to be reduced range.
- \* The frequency of swallowing:
  - It varies with activity.
  - It is very repetitive (> 2,000 swallows per day) [1].
  - Mean swallowing frequency is about 580 swallows per day.
  - The swallowing frequency is greater during eating.
- \* Frequency of spontaneous swallows of saliva averages about once every 1 to 2 minutes, and an increase in salivary flow and rate of swallowing occurs on stimulation with certain odors or actual food in the mouth, or with the presence of an endoscope in the hypopharynx [2].
- \* Endoscopy can assess real-life saliva swallowing, whereas fluoroscopy cannot [2].
- \* There are four phases for the act of swallowing 1) the oral preparatory phase, 2) the oral phase, 3) the pharyngeal phase, and 4) the esophageal phase [3]

## The process of swallowing and sensitive triggering points:

- ...semi-automatic contraction and relaxation of the 55 muscles of the oropharyngeal, laryngeal and oesophageal regions, 6 cranial nerves, and 2 cervical nerve roots [4], which are modulated by afferent stimuli to the brainstem swallowing center.
- \* Swallowing depends on a central pattern generator (CPG) located in the medulla oblongata, which involves several brain stem motor nuclei (V, VII, IX, X, XII) and two main groups of interneurons: one in the dorsal medulla within the nucleus tractus solitarii and in the adjacent reticular formation and another in the ventrolateral medulla, just above the nucleus ambiguus. The CPG for swallowing consists of two hemiCPGs each located on one side of the medulla that are tightly synchronised and organise the contraction of the bilateral muscles of the oropharyngeal region. All of the swallowing events until the oesophageal phase are mainly controlled by the CPG. Swallowing activity is integrated in multiple cranial nerve (CN) nuclei. Taste sensation is mediated through CNs VII, IX. Motor efferents include CN V and VII, IX, XII, and CN X. CNs V, IX, X and XI are involved in the reflexive swallow and pharyngeal and upper oesophageal phases of feeding [5]
  - \* The process of swallowing is organized with sensory input from receptors in the base of the tongue, soft palate, faucial arches, tonsils, and the posterior pharyngeal wall, which then is transmitted to **the swallowing center located within the medulla oblongata and pontine reticular system (Brainstem)** through the facial

(VII), glossopharyngeal (IX), and vagus (X) cranial nerves. The swallow is primarily controlled in the brainstem where the swallow stimulus is identified and sending this information to the nucleus ambiguus, which initiates the pharyngeal swallow action.

- \* Information from the swallowing center then is conveyed back to the muscles that help in swallowing through trigeminal (V), facial (VII), glossopharyngeal (IX), vagus (X), and hypoglossal (XII) cranial nerves, with the trigeminal, hypoglossal, and nucleus ambiguus constituting the efferent levels [6]
- \* The most sensitive oropharyngeal mucosal receptor regions for the stimulation of the swallowing sequence are innervated by fibers of the glossopharyngeal nerve via the pharyngeal plexus and by the superior laryngeal nerve (SLN) via the vagus nerve. Stimulation of the SLN induces pure swallowing with a short latency, and this finding has led to the belief that the fibers of the SLN constitute the main afferent pathway involved in the initiation of swallowing [7]
- \* Stimulation of the glossopharyngeal nerve facilitates swallowing, but alone, does not trigger the pure motor pattern of oropharyngeal swallowing. Both the glossopharyngeal and the SLN send fibers to the nucleus tractus solitaries (NTS) in the brainstem. The NTS is the principal sensory nucleus of the pharynx and esophagus and all the afferent fibers involved in initiating or facilitating swallowing converge in the NTS, mainly in the interstitial subdivision. Almost all of the NTS neurons that are involved in swallowing are activated with stimulation of The SLN [7]
- \* Many of the neurological disorders that result in dysphagia do not involve the brain but rather affect a wide range of supramedullary central neural regions [7]
- \* In addition, the fact that swallowing can be initiated voluntarily without stimulation of the pharynx by a bolus, such as in a “dry” swallow, indicates that input from cerebral cortex can trigger swallowing [7]
- \* There are a number of subcortical sites, including the corticofugal swallowing pathway, which can trigger or modify swallowing, in particular the internal capsule, subthalamus, amygdala, hypothalamus, substantia nigra, mesencephalic reticular formation, and a monoaminergic brain stem nuclei [7]
- \* Many studies of central swallowing control emphasize the importance of the inferior precentral gyrus.
- \* The anterior insula/clastrum and the cerebellum are also likely active in the initiation of voluntary swallowing.
- \* The dorsal swallowing group (DSG) of interneurons is located in the dorsal medulla within the NTS and adjacent reticular formation [7]
- \* The ventral swallowing group (VSG) of interneurons is located in the ventrolateral medulla just above the nucleus ambiguus [7]
- \* The motor nuclei of the nucleus ambiguus control the pharyngeal muscles [7]
- \* DSG interneurons are thought to be involved in triggering, shaping, and timing the sequential swallowing motor pattern. These interneurons exhibit a sequential firing pattern that parallels the sequential motor pattern typical of deglutition, with considerable overlap between the sequential firing of the various neurons [7]

- \* Each DSG neuron may be directly activated by signals from peripheral afferent fibers originating in the corresponding part of the oropharynx that is under its control.
- \* Some of the neurons in the DSG exhibit activity before the onset of the swallowing motor sequenced which is continuous and is called “preswallowing activity.” Those DSG interneurons that display preswallowing activity can be activated by stimulation of both the SLN and the glossopharyngeal nerve. This pattern of activity observed in the DSG interneurons suggests that these neurons are involved in the initiation of swallowing [7].
- \* The interneurons of the VSG are thought to be “switching” neurons that distribute and coordinate the swallowing drive to the various pools of motor neurons involved in swallowing. The firing behavior of these neurons also exhibits a sequential pattern, but with more overlap, longer latency, greater duration variability, and lower frequency than the interneurons of the DSG [7].
- \* The VSG interneurons are probably activated by the interneurons of the DSG.
- \* The trigeminal and hypoglossal motor nuclei are connected only to the VSG interneurons and not to the DSG [7].
- \* Swallowing motor neurons only receive input from the ipsilateral efferent fibers of the ventral swallowing interneurons [7].
- \* In conclusion, the DSG interneurons are involved in initiating the swallowing sequence. They stimulate the interneurons of the VSG which then modulate and coordinate the stimulation of the various motor neurons involved in the swallowing sequence.
- \* Within the central pattern generator some neurons may participate in activities other than swallowing such as respiration, mastication, and vocalization. Respiration is also likely controlled via a central pattern generator that coordinates with the swallowing pattern generator to integrate swallowing and respiratory functions [7].

### **The sensitive triggering points**

- \* Within the oropharynx, **the faucial pillars** are the most sensitive region for eliciting a swallow [2].
- \* Whereas studies have shown that tactile, taste, and temperature information about a bolus will be sent to the brain as soon as it enters the **mouth** [2].
- \* Only minority of the swallows were initiated while the bolus was in the **mouth**, with 76% of the solid food and 60% of the liquid swallows initiated after the bolus had entered the hypopharynx [2].
- \* The receptors on structures closest to the **lower airway** would be most sensitive to the presence of a bolus and would signal the brain to initiate a swallow [2].
- \* The densest regions of sensory receptors lie within the **larynx**, along the laryngeal surface of the epiglottis, along the aryepiglottic folds, on the arytenoids, and on the false vocal folds and the true vocal folds. Any contact of the bolus with the larynx itself seems to trigger a swallow in a normal person [2].
- \* Receptors in the **laryngeal mucosa** are most sensitive to water, whereas receptors in the oral cavity and pharynx are most responsive to other tastes [2].

- \* It was not uncommon for the boluses to touch the **laryngeal** rim or the epiglottal edge as they moved down the pharynx (12% of liquids and 34% of solid food), and most of these encounters triggered a swallow before reaching the pyriforms [2]
- \* It was concluded that the **valleculae** are not sensitive trigger points for the swallow. The valleculae seemed insensitive to fluid filling, but pharyngeal and laryngeal structures inferior to the valleculae were more sensitive triggering zones. It was noteworthy that the - normal subjects did not swallow when the bolus was infused into the valleculae [2]
- \* It was not uncommon for liquid and solid food boluses to reach the **valleculae** before the swallow began (37% of liquids and 40% of solids), but far fewer boluses traversed as far as the pyriforms (11% of liquids and 2% of solid food boluses).
- \* Material could rest in the **valleculae** for several seconds before the swallow began (liquids,  $3.2 \pm 0.5$  seconds; solid food,  $2.1 \pm 0.3$  seconds). When material fell to the pyriforms, it dwelled there for a shorter period (liquid,  $1.4 \pm 0.6$  seconds; solid food,  $1.5 \pm 0.7$  seconds). When material encroached on the **laryngeal** vestibule by resting on the epiglottal edge or rim of the aryepiglottic folds, the swallow was initiated quickly (Liquid,  $0.3 \pm 0.04$  seconds; food,  $0.4 \pm 0.05$  seconds) [2]
- \* For most normal swallows, we do not initiate the swallow when the bolus is in the mouth, moving past the faucial pillars, or even midway down the base of tongue. Rather, we let both liquid and solid food travel to the hypopharynx before we initiate swallowing.
- \* The most common pattern, it appears, is to swallow soon after the material leaves the valleculae. As long as the bolus stays away from the laryngeal rim, including the tip of the epiglottis, superior edge of the aryepiglottic folds, tips of the arytenoids, and interarytenoid space, we seem to be able to inhibit swallowing [2]

## Oral preparatory phase of Swallowing:

- \* Orbicularis Oris closes oral chamber to maintain pressures, and prevents the bolus from leaking out of the mouth during the oral phase. (See Figure 1)
- \* Buccinator muscle tenses the cheek thus maintaining food between the molars; the muscle is also active when sucking and expelling air forcibly.
- \* Muscle "sling" contraction and compression of chamber by the action of Orbicularis oris, Buccinator, and Superior pharyngeal constrictor muscles will create positive pressure in oral chamber. (See Figure 2).
- \* Chewing food to form the bolus [8] by the action of masseter, temporalis, Internal (Medial) Pterygoid, External (Lateral) Pterygoid, and Supra- and Infrahyoid muscles.

- \* These muscles are responsible for closing and opening the jaw and keeping the mouth closed while chewing.
- \* During this phase of swallowing:
  - The larynx and pharynx are at rest.
  - The airway is open and
  - nasal breathing carries on.
- \* Based on the viscosity of the food, there will be a variation in the volume of bolus swallowed. So, the maximum volume swallowed decreases when the bolus viscosity increases.



Figure 2. Oral chamber [1]

## The oral phase of Swallowing:

- \* It is considered under voluntary cortical control.

### Oral Transit Time

- \* It is defined as the time taken from the initiation of the tongue movement until the bolus reaches the tongue base where it crosses the lower edge of the mandible.
- \* This phase begins when the bolus is pushed backward by the posterior part of the tongue and ends as the bolus passes through the anterior faucial arches until the bolus reaches the tongue base where it crosses the lower edge of the mandible.



Figure 1. Lip seal [1]

- \* It was reported that it to be only 0.5 seconds if counting begins when the tongue tip touches the incisors [2].
- \* The oral phase is approximately completed in less than **1-1.5 seconds** (oral transit time), which increases as the bolus viscosity increases.

### **Normal structural movement during oral swallow**

- \* Pushing the bolus upward and backward against the undersurface of the hard palate by the contraction of the styloglossus muscle pulling the root of the tongue upward and backward.
- \* The bolus is squeezed backward into the oral part of the pharynx by the action of palatoglossus muscle until the pharyngeal wall is triggered.
- \* Sometimes part of the bolus is retained in the mouth for another cycle. Hence, transporting, "dumping", or thrusting food into the valleculae during oral preparation is normal [2].
- \* Toward the end of mastication, the tongue normally transports a portion of a solid food bolus into the hypopharynx [2].
- \* Liquids only occasionally are seen in a normal swallow because the amount allowed to spill into the pharynx before onset of the swallow is often minimal [2].

### **The oral phase requires the following:**

- 1) Adequate mouth closure that is brought by intact labial muscles to prevent any leaking out of the oral cavity.
- 2) Intact buccal muscles to prevent food materials to fall into the lateral sulci.
- 3) Propelling the bolus posteriorly by intact lingual muscles movement.
- 4) Comfortable nasal breathing.

### **The pharyngeal phase of Swallowing:**

- \* The pharyngeal stage of the swallow is involuntary and primarily controlled reflexively
- \* 90% of the swallow occurs during expiration
- \* An apneal pause between **1 and 3.5 seconds** in duration occurs during the pharyngeal stage.
- \* This phase begins when the pharyngeal swallow is triggered and the bolus is moved through the pharynx, and it ends by opening the upper esophageal sphincter (Cricopharyngeal sphincter).
- \* The pharyngeal phase of swallowing is completed when the soft palate returns to its original position and the larynx is reopened for respiration.
- \* Both laryngeal elevation (which pulls the cricoid lamina away from the posterior pharyngeal wall) and cricopharyngeal relaxation are essential for normal opening of the pharyngo-esophageal segment for bolus passage [7].
- \* Manometric studies have shown that a successful swallow depends on the tongue driving pressure and the negative pressure developed in the PE segment more than the peristaltic-like pressure of the constrictors [7].

### Pharyngeal transit time (PTT)

- \* PTT (**0.85-1.15 sec.**) is the time taken from the bolus passing the base of the tongue until the bolus passes through the pharyngoesophageal segment [9].
- \* It is **0.32 seconds** for small volume swallows and increase as volume increases.
- \* However, a study showed that the analysis of 60 younger normal swallow subjects (age 18-65) revealed no change in pharyngeal transit time across bolus size or consistency [10].
- \* PTT can be broken into two parts:
  - pharyngeal delay time (when bolus first enters pharynx until structural movements begin), and
  - pharyngeal response time (when structural movements begin until bolus passes through UES) [2].
- \* Ironically, the measure of PTT, which began as a measure of how long it took the bolus to traverse the pharynx, has evolved to the point where the duration of the pharyngeal swallow is now defined by some investigators as a measure of structural movements entirely, without consideration of the bolus [2].
- \* Palmer found that "oral processing" times and "vallecular aggregation" times increased with the hardness of the food, but the duration of the pharyngeal swallow (time from onset to completion of the pharyngeal response) was remarkably uniform, regardless of the consistency of the bolus [2].

### Pharyngeal response time

- \* Pharyngeal response time varied from **0.84 to 0.88 seconds** [2].
- \* It is measured from onset of laryngeal elevation until the bolus passes through the cricopharyngeal sphincter or until the cricopharyngeal sphincter closes [9].
- \* Unlike pharyngeal delay time, pharyngeal response time is much more constant.

### Pharyngeal delay time

- \* Pharyngeal delay times vary from **0.11 seconds to 1.58 seconds**.
- \* Pharyngeal delay time is measured and the **location of the bolus** during the delay should be **identified**.
- \* It begins when the bolus reaches the tongue base where it crosses the lower edge of the mandible and ends when laryngeal elevation begins.
- \* The first landmark for starting to count a pharyngeal delay is the anterior faucial arches in a young person. In an older person, this landmark is the intersection of base of tongue/ ramus of mandible [2].
- \* Endoscopy and fluoroscopy measure pharyngeal delay in a similar manner. Counting begins when the bolus head appears in view at the base of the tongue, which corresponds to the landmark established fluoroscopically for older persons [2].
- \* Pharyngeal delay ends when the epiglottis begins its retroflexion, which corresponds to the onset of hyoid elevation, or, if this is not clearly visible, counting stops at whiteout [2].
- \* In short, they found that some delay is common with liquids and is to be expected with solid food.



- \* In normal adult over age 60, there is normal delay of pharyngeal swallow by **0.4 – 0.5 seconds**. The triggering of the pharyngeal swallow has been noted to occur later, when the bolus reaches past the faucial arches to approximately the middle of the tongue base. But, it is considered abnormal when a delay is more than 2 seconds with aspiration occurrence.
- \* In infant, more than 1 second between the last tongue pump and the onset of the pharyngeal swallow, or when aspiration occurs during bolus collection, is considered as an abnormal delay.

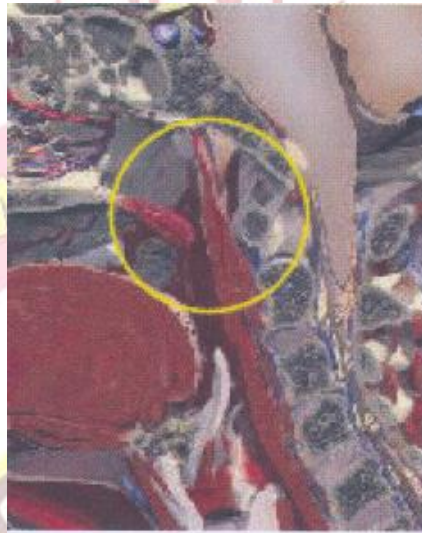

Figure 3. Velopharyngeal seal [1]

### **Hyoid elevation time**

- \* The duration of hyoid elevation until its return to rest was **1.00 second** [2].
- \* Measured fluoroscopically counting begins when the bolus head passes a given landmark and ends when the hyoid or larynx begins its final elevation [2].

### **Normal structural movement during pharyngeal swallow**

- \* As a result of pharyngeal triggering, the following will result:
  - (a) The nasal part of the pharynx is now shut off from the oral part of the pharynx by →**
- \* The velum is raised, primarily by the levator and tensor veli palatini muscles. This prevents the entry of food into the nasopharynx. In a lateral plane, fluoroscopy captures velar contact against the posterior pharyngeal wall, but it cannot determine whether the contact is complete unless the bolus penetrates this seal [2].
- \* Nasopharyngeal closure began almost simultaneously with relaxation of the UES and the onset of vocal cord adduction or initial arytenoid adduction [2]. Thus, velopharyngeal closure is another early marker of the onset of the swallows [2].
- \* The Levator veli palatine contraction and the contraction of superior pharyngeal constrictor muscle (narrows the upper pharynx) help seal the velopharyngeal port that close pharyngeal chamber to maintain pressures (see Figure 3).

**(b) The tongue is retracted, preventing the food from re-entering the mouth.**

- \* Styloglossus, Superior pharyngeal constrictor, Hyoglossus & Palatoglossus pull the



Figure 5. Oropharyngeal seal [1]

tongue backward at the beginning of the pharyngeal phase, propelling the bolus into the pharynx. This results in increased oro-pharyngeal pressure, increased intra bolus pressure and effectively seals off the oral cavity from the oro-pharynx.

- \* This propulsive force generated by the tongue (also referred to as the tongue driving force) is the most important of these factors (See Figure 4).
- \* Moreover, Intrinsic & Extrinsic tongue muscles, Palatoglossus, Stylopharyngeus close off oropharyngeal seal to maintain pressures (see Figure 5).

**(c) The pulling forward of the posterior pharyngeal wall**

- \* The longitudinal pharyngeal muscles (i.e., the stylopharyngeus, salpingopharyngeus, palatopharyngeus, and palatothyroideus) counterbalance the contraction of anterior floor of mouth muscles [2] These muscles squeezes the

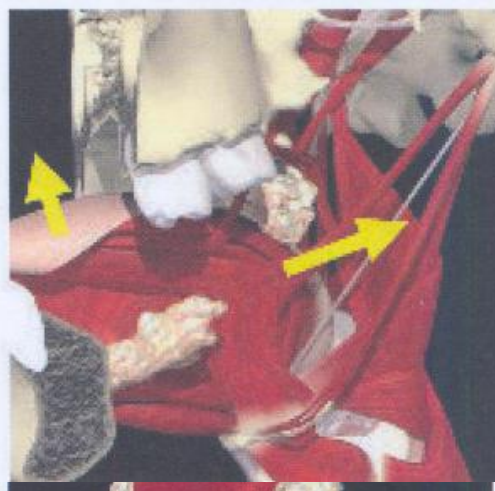

Figure 4. Tongue base retraction [1]

Figure 6. Compression pharyngeal chamber [1]

pharynx laterally and AP, and shortens the pharynx that will increase the pressure in pharyngeal chamber and assist UES opening (see Figure 6)

- \* Miller and Watkin (1997), using ultrasound, reported that each lateral pharyngeal wall was displaced an average of 1 to 1.23 cm during the swallow, contacting the opposite wall medially in some cases [2]
- \* Pharyngeal shortening elevates the pharynx about 2.2 cm, bridging the upper esophageal sphincter (UES) to within 1.5 cm of the tongue base, and empties the contents of the pyriform sinuses into the open UES [2]

#### (d) The entrance into the larynx is closed now

- \* It is closed by pulling upward of the larynx (approximately 2 cm in normal young adult men) and laryngeal part of the pharynx that is brought by the contraction of  
→
  - Stylopharyngeus,
  - Salpingopharyngeus,
  - Palatopharyngeus muscles, and

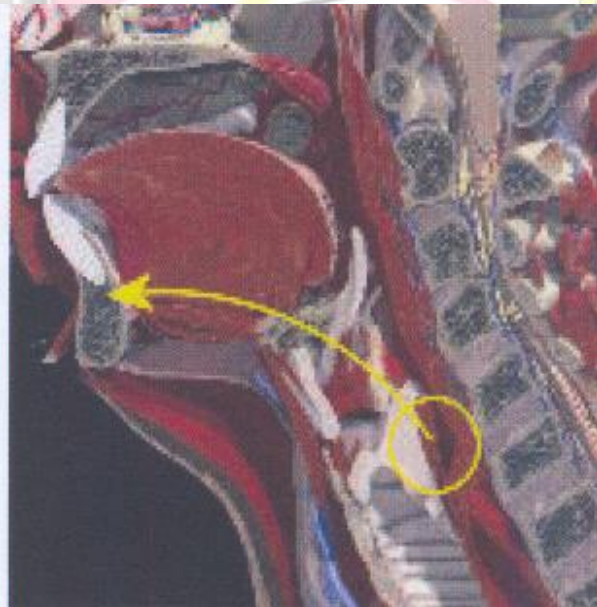

Figure 7. Hyolaryngeal excursion [1]

- Thyrohyoid.
- \* Hyolaryngeal excursion (see Figure 7): The larynx and the hyoid bone are pulled both upward and forward (Hyoid moves superiorly; Hyoid moves anteriorly; Hyoid and thyroid approximate) by the Suprahyoid and Infrahyoid muscles, which will
  - Enlarges the pharynx
  - Creates a vacuum in the hypopharynx, pulling the bolus downward
  - Contributes to the relaxation of the cricopharyngeus muscle
- \* With fluoroscopy, one of the first structural movements that can be visualized to signal the onset of the swallow is hyoid and laryngeal elevation.
- \* The larynx moves superiorly about 2.5 cm, the hyoid moves about 1.1 cm superiorly and 0.9 cm anteriorly [2]

- \* Larynx closes at three valves:
  - The arytenoids to base of epiglottis
  - The true vocal folds
  - False vocal folds (i.e., the airway entrance).
- \* Recent investigation has shown the order of closure to be as follows:
  - 1) arytenoids move medially and then anteriorly to touch or squeeze against the base of the epiglottis; (This occurs approximately 0.341 seconds (or 11 frames on videotape) before initial hyoid elevation. [2]) This anterior movement also can be seen fluoroscopically, but not as precisely as with endoscopy [2]
  - 2) the epiglottis inverts to cover the arytenoids; finally,
  - 3) the true and false vocal folds adduct [2]
  - This pattern of airway closure is unique to swallowing.
  - In breath-holding, cough, or other protective behaviors, the true vocal folds appear to adduct at the start of the movement [2].
  - Airway closure for swallowing takes approximately 0.6 seconds to be complete; suggesting that the airway is vulnerable to an advancing bolus for more than half a second after the swallow has begun [2]
  - Airway closure is the first event to mark the onset of the swallow [2].
  - Shaker et al (1990) described the initial closure as complete, with the true vocal folds adducting along with arytenoid medialization [2].
  - Ohrae (1995, 1996) and McCulloch (1993, 1998) and their colleagues both reported that the initial medial contact of the arytenoids did not generally correspond to closure of the true vocal cords [2].
  - Both groups noted that as the larynx elevated and the arytenoids tilted anteriorly to touch the epiglottis, the vocal folds often could be seen endoscopically to "reopen," and at whiteout, the vocal cords were still open 94% of the time [2].
  - In normal swallows, the bolus may fall into the hypopharynx and reach the pyriform sinuses well before the vocal folds adduct [2].
  - Neither fluoroscopy nor endoscopy captures this moment of true vocal-fold adduction directly [2]
- \* The bolus moves downward over the epiglottis and reaches the lower part of the pharynx due to the successive contraction of the superior, middle, and inferior constrictor muscles.
- \* The epiglottis drops down over the top of the larynx:
  - a) Protects the airway
  - b) Diverts the bolus into the pyriform sinuses
  - c) Bolus passes down on both sides of the epiglottis
  - d) If the bolus is liquid, the epiglottis acts as a ledge to slow its movement through the pharynx, giving the vocal folds time to adduct and the larynx time to elevate.
- \* Laryngeal seal: Hyolaryngeal excursion, epiglottic deflection/inversion, vocal cord adduction by the action of Suprahyoids and thyrohyoid, Aryepiglotticus and thyroepiglotticus, Vocal cord adductors will close laryngeal vestibule to protect airway (see Figure 8).

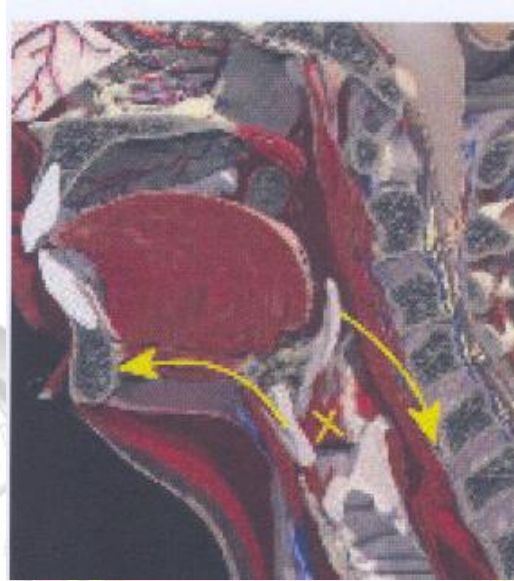

Figure 8. Laryngeal seal [1]

**(e) The cricopharyngeal sphincter is opened to allow material to pass through into the esophagus.**

- \* Relaxation of the UES occurs early, soon after the arytenoids begin to medialize.
- \* Three factors cause food to move down the pharynx during the rest of the pharyngeal stage:
  - 1) The propulsive action of the “pharyngeal tongue”
  - 2) The presence of positive pressure in the oropharynx, which is caused by combined action of the pharyngeal tongue, the presence and movement of the bolus and the contraction of the pharyngeal constrictors. The stripping action of the pharyngeal constrictors. Contractions of pharyngeal constrictors during swallowing is submaximal; speed and timing of contraction of these muscles is more important than strength.
  - 3) The presence of negative pressure in the hypopharynx space by the action of Stylopharyngeus muscle will expand the hypopharynx (see Figure 9).
- \* The pharyngeal stage ends when the cricopharyngeus muscle relaxes, allowing the bolus to enter the esophagus. It is believed that the following three factors affect the opening of the cricopharyngeus, although the process is not currently well-understood:
  - 1) Innervation by the vagus nerve
  - 2) Timing of the stripping action in the pharynx
  - 3) Elevation of the larynx which may pull the muscle upward, causing it to open by stretching it and therefore causing it to relax

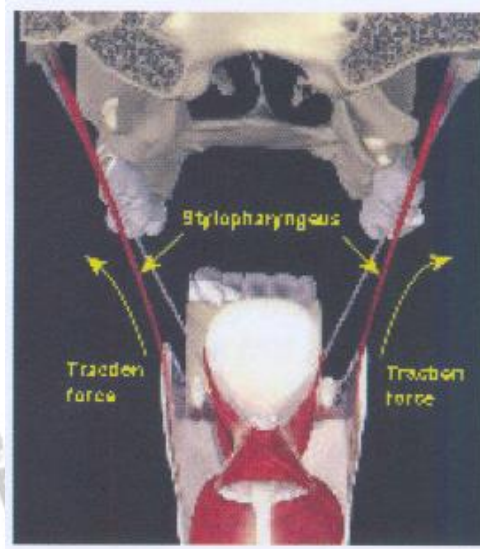


Figure 9. Expansion of hypopharynx [1]

## The esophageal phase:

- \* This phase begins when the bolus enters the esophagus where it is carried through the esophagus in peristaltic motion until the lower esophageal sphincter (Lower gastroesophageal sphincter) opens to allow the bolus to enter the stomach.
- \* Esophagus begins peristaltic motion by the action of Esophageal musculature, which creates positive pressure in esophageal chamber to move bolus toward stomach as seen in Figure 10.
- \* This stage normally lasts up to ten seconds (1-3 seconds for liquids and very soft foods, 4-10 seconds for soft and solid foods); in elderly persons peristalsis is slower (up to 20 seconds)
- \* The esophageal stage commences with the lowering of the larynx, the constriction of the cricopharyngeus muscle to guard against reflux of food.
- \* LES relaxes, opens, and finally closes to control access to stomach.

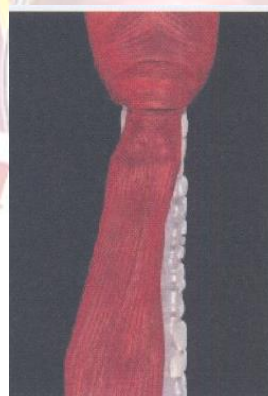

Figure 10. Compression esophageal chamber [1]

## Works Cited

- [1] Y. Wijting and Freed, M., *VitalStim therapy training manual*, Gulf Breeze, FL: Career Improvement & Advancement Opportunities (CIAO), 2006.
- [2] S. Langmore, "Normal swallowing: The Endoscopic perspective," in *Endoscopic evaluation and treatment of swallowing disorders*, New York, NY: Thieme New York, 2001, pp. 50-59.
- [3] J. Logemann, "Anatomy and physiology of normal deglutition," in *In Evaluation and treatment of swallowing disorders*, 2nd ed., Austin, Texas: Pro.ed., 1998, pp. 23-35.
- [4] K. Lim, Lee, H., Lim, S. and Choi, Y., "Original report neuromuscular electrical and thermal-tactile stimulation for dysphagia caused by stroke : A randomized controlled trial," *Journal of Rehabilitation Medicine*, vol. 11, pp. 174-178, 2009.
- [5] R. Marchese-Ragona, D. Restivo, G. Marioni, G. Ottaviano, S. Masiero and A. Staffieri, "Evaluation of swallowing disorders in multiple sclerosis," *Neuroscience*, vol. 27, p. S335-S337, 2006.
- [6] S. Dawodu, "Swallowing Disorders," 2007. [Online]. Available: <http://www.emedicine.com/pmr/TOPI152.HTM>. [Accessed 25 July 2008].
- [7] R. Leonard and Kendall, K., *Dysphagia assessment and treatment planning: a team approach*, 2nd ed., San Diego, CA: Plural Pub, 2008, p. 345.
- [8] R. Snell, "The head and neck," in *Clinical anatomy for medical student*, 5th ed., Boston, NY: Little, Brown, 1995, p. 744.
- [9] J. Logemann, *Evaluation and treatment of swallowing disorders*, 2nd ed., Austin, Texas: Pro-Ed, 1998.
- [10] R. Leonard and Kendall, K., "Dynamic swallow studies: Measurement techniques," in *Dysphagia assessment and treatment planning: a team approach*, 2nd ed., San Diego, CA: Plural Publishing, 2008, pp. 292-294.